

Case Report

Perforation of Meckel's diverticulum with peritonitis: rare case report and review of literature

Abdul Rafe, Maroti P. Pote, Unmesh Vidyadhar Takalkar*

Department of Surgery, Govt. Cancer Hospital & Medical College, Aurangabad, Maharashtra, India

Received: 27 May 2015

Revised: 15 July 2015

Accepted: 24 July 2015

*Correspondence:

Dr. Unmesh Vidyadhar Takalkar,

E-mail: drunmesh.aurangabad@gmail.com

Copyright: © the author(s), publisher and licensee Medip Academy. This is an open-access article distributed under the terms of the Creative Commons Attribution Non-Commercial License, which permits unrestricted non-commercial use, distribution, and reproduction in any medium, provided the original work is properly cited.

ABSTRACT

Meckel's Diverticulum (MD) is the most common congenital anomaly of the small bowel found in 2% of population. The majority of patients with this anomaly will remain asymptomatic; however, several complications can occur, including obstruction, intussusceptions, hemorrhage and diverticulitis. Perforation of Meckel's diverticulum is rare complication occurring in less than 7% of patients complicated by Meckel's diverticulum that can often mimic appendicitis. Preoperative diagnosis of perforated Meckel's diverticulum remains a challenging issue. This case demonstrates that a healthy degree of suspicion for complicated Meckel's diverticulum should be present when dealing with a questionable diagnosis of appendicitis. We report case of 19 years old boy who presented to emergency department with abdominal pain in right lower quadrant mimicking perforated appendicitis. Exploratory laparotomy disclosed normal appendix and perforation of Meckel's diverticulum.

Keywords: Meckel's diverticulum, Perforation, Acute appendicitis

INTRODUCTION

Meckel's diverticulum is the most prevalent congenital anomaly of the gastro intestinal tract, affecting approximately 2% of the general population. Their location varies among individual patients, but they are usually found in the ileum within 100 cm. of ileocaecal valve.

Approximately 60% of Meckel's diverticulum contains hetero topic mucosa, of which over 60% consist of gastric mucosa.¹ It possesses all the three layers of intestinal wall and has its own blood supply from superior mesenteric artery, which makes it vulnerable to infection and obstruction like appendix.²

Majority of the Meckel's diverticulum remain silent and are diagnosed incidentally during investigations or procedures done for unrelated condition, or until

complications arise from the diverticulum.³⁻⁴ A person with Meckel's diverticulum has a 4-6% lifetime risk of developing a complication⁵ with a male to female ratio ranging from 1.8:1 to 3:1.⁶ The most clinical presentation is GI bleeding in pediatric age group. Other complications include obstruction, intussusceptions and diverticulitis with perforation occurring rare in less than 7% of patients having complication.⁷ This is an interesting and unusual case of spontaneous perforation of Meckel's diverticulum in a young adult.

CASE REPORT

A previously healthy 19 years old indo-Aryan male presented to us with one day history of abdominal pain and fever without chills since 8 hrs. He denied any other symptoms apart from nausea. He gave history of pain was with sudden onset, started in right lower quadrant of abdomen. Later it became generalized. He denied any

history of preceding viral illness, ingestion of foreign body, diarrhea or bloody stool.

On examination, patient was febrile having 101°F. His pulse rate was 100/min and BP was 110/70 mmHg. Examination of abdomen showed tenderness all over the abdomen, rigidity and voluntary guarding in periumbilical part and right lower quadrant. Bowel sounds were present but diminished throughout. The remainder of his physical exam was unremarkable and within normal limits for his age.

Initial laboratory work up revealed an elevated blood count; his white blood cells were 18700/mm³, with 90% neutrophils. The rest of the routine preoperative blood tests and his chest and abdominal X-rays were unremarkable. Ultrasound showed free air in abdomen with moderate free fluid with internal echoes within secondary to bowel perforation. A CT scan of the abdomen and pelvis was obtained, which demonstrated free air and a moderate amount of free fluid in the pelvis tracking up the gutter. An enhancing collection with surrounding inflammatory changes was visualized in the patient's midline.

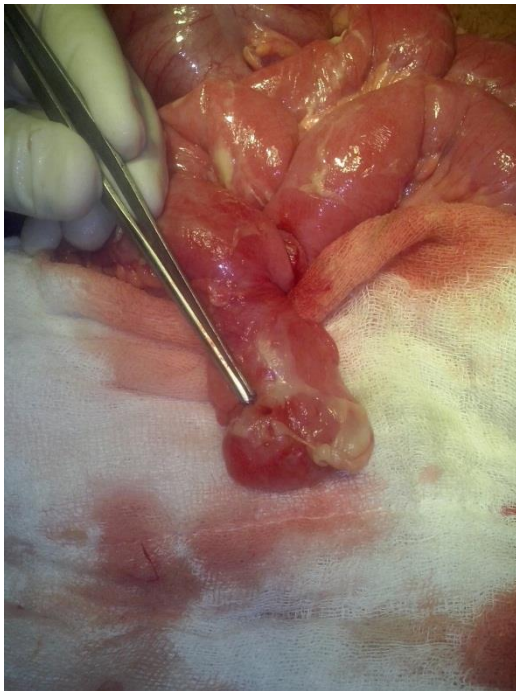


Figure 1: Showing perforation of Meckel's diverticulum at tip.

Provisional diagnosis of perforated appendix with peritonitis was made and patient underwent open laparotomy. On examination, normal appearing appendix with caecum was found. An examination of the small bowel revealed an inflamed and perforated Meckel's diverticulum, containing fecolith, about 80 cm away from ileocaecal valve (Figure 1 & 2). Wedge resection of the perforated Meckel's diverticulum was performed with primary anastomosis of the adjacent small bowel (Figure

3). The operational site was irrigated with normal saline solution. Gross pathologic examination of the surgical specimen confirmed a perforated Meckel's diverticulum with extensive acute inflammation of the adjacent small bowel (Figure 4). A histologic examination of the Meckel's diverticulum did not reveal gastric- or pancreatic-type mucosa. The patient made an uneventful recovery postoperatively and was discharged on the seventh postoperative day. At the follow-up examination at 1 month after surgery he was doing well.

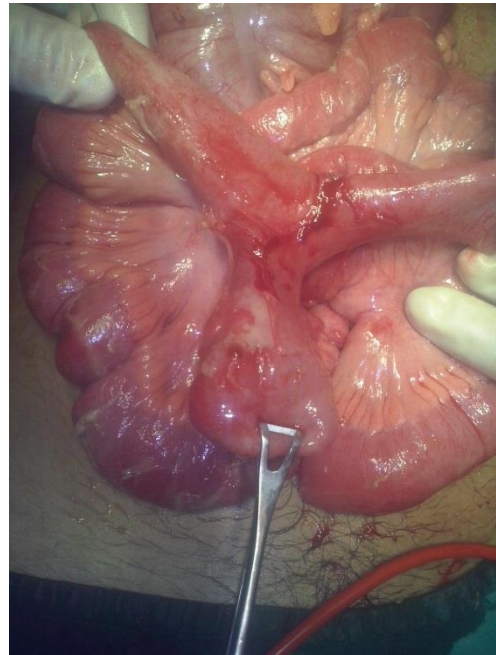


Figure 2: Shows Meckel's diverticulum in terminal ileum containing fecolith along with perforation.

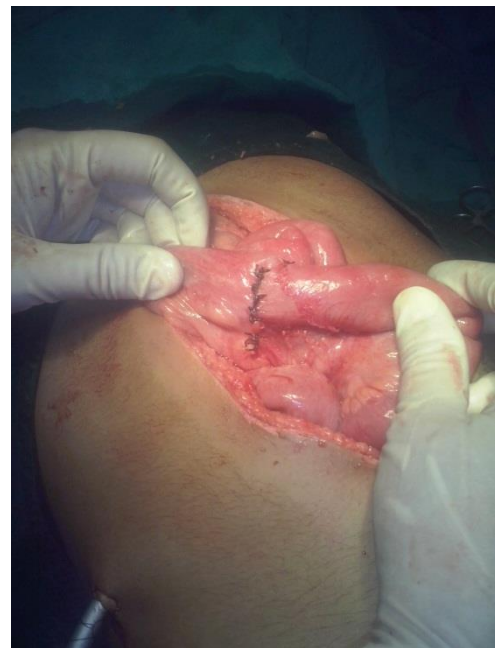

Figure 3: Shows anastomosed ileum after resection of Meckel's diverticulum.

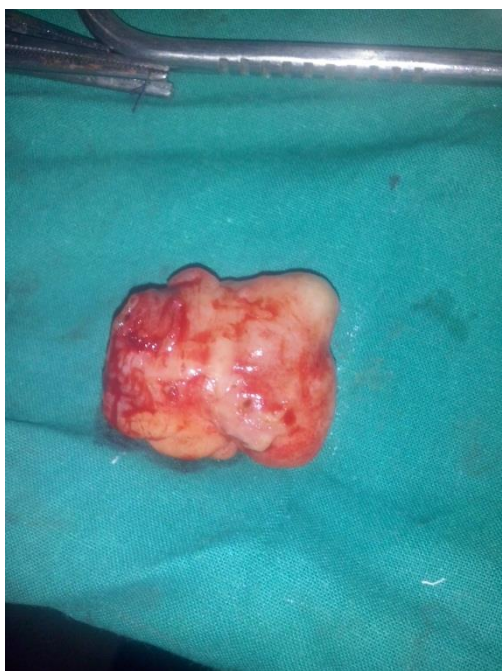

Figure 4: Shows resected specimen of Meckel's diverticulum.

DISCUSSION

Meckel's diverticulum is the most common congenital abnormality of gastro intestinal tract, found in approximately 2% of general population.⁸ MD is a congenital, intestinal blind pouch that results from an incomplete obliteration of vitelline duct during fifth week of gestation. It is located on anti-mesenteric border of ileum 45-60 cm proximal to ileocaecal valve and is usually 3-5 cm long.² It possesses all three layers of intestinal wall and has its own blood supply from superior mesenteric artery, which makes it vulnerable to infection and obstruction like appendix.²

Although it generally remains silent, life threatening complications may arise, making it important to have a detailed knowledge of its anatomical and patho physiological structure and properties to deal with such complications.⁹ Hemorrhage is the most common presentation in children while in adults intestinal obstruction is the most common complication.

Intussusceptions, inflammation and neoplasm are other known complications while perforation is rare. Study by Yamaguchi and colleagues showed the following complication rate: obstruction-36.5%; intussusceptions-13.7%; diverticulitis-12.75; hemorrhage-11.8% and perforation 7.3% only.¹⁰

Meckel's diverticulum is notoriously difficult to diagnose both clinically and radio logically as symptoms and imaging features are non-specific and are often indistinguishable from acute appendicitis until visualization in operating room. Interestingly, in a study

of 600 cases, Yamaguchi et al. reported a preoperative diagnostic rate of only 5.7%.¹⁰ The most frequent initial diagnosis has been reported to be acute appendicitis. This happens, since as in our case, right lower quadrant abdominal pain is usually attributed to appendiceal inflammation. The diagnosis of ruptured Meckel's diverticulum was ultimately made by laparotomy. It is difficult to diagnose the site of perforation prior to exploration. It typically presents with features similar to that of perforation of other hollow viscera, with features of either localized or generalized peritonitis. Various etiologies that can lead to perforation of Meckel's diverticulum are a) progression of diverticulitis b) ulceration of adjacent ileal mucosa secondary to acid produced by ectopic gastric mucosa c) secondary to ingested foreign bodies like fish bone,¹¹ chicken bone and bay leaf d) trauma.¹² In addition, obstruction of diverticular lumen by a fecolith may lead to inflammation, necrosis and eventual perforation. Interestingly our patient's Meckel's diverticulum did not contain ectopic gastric mucosa on histological examination of specimen. As fecolith was present in Meckel's diverticulum, in our case, it may be source of perforation given the lack of trauma, foreign body and ectopic gastric mucosa.

Radiological diagnosis of Meckel's diverticulum can be difficult particularly when diagnosis is not initially suspected. Ultrasound is often used in the setting of non-specific abdominal pain; however it is of limited value for diagnosing Meckel's diverticulum except in the case of intussusception.¹³ Inflammatory changes and extra luminal air may be present on CT scan, but a higher degree of suspicion for Meckel's diverticulum must be present, as this can resemble other common conditions.¹⁴ The technetium-99 m pertechnetate scan, or Meckel's scan, is generally regarded as the most accurate, non-invasive diagnostic technique. However, false-negative rates are higher in patients without bleeding, and ectopic gastric mucosa must be present in the MD for a positive result. In our patient, appendicular perforation was suspected on CT scan and ultrasonography because of inflammatory changes and free air in peritoneal cavity. Additionally patient had no rectal bleeding. Meckel's scan was not performed as clinically Meckel's diverticulum was not suspected. Due to the lack of ectopic gastric mucosa in the resected specimen, the scan would not have assisted in diagnosis even if performed.

Management of complicated Meckel's diverticulum consists of diverticulectomy in the majority of cases or segmental ileal resection along with antibiotics and peritoneal irrigation in case of localized or generalized peritonitis. Early intervention is crucial especially when the patient's state deteriorates. Cullen and others conducted an epidemiological study at the Mayo clinic in Minnesota that found the incidence of complications requiring surgery to be 6.4%, with no trend related to age. The mortality rate of these patients was

1.5%, with 7% morbidity; incidental removal had 1% mortality and 2% morbidity.⁶

There are several studies stating the safe and effective use of laparoscopy in case of complicated Meckel's diverticulum.^{15,16} It can be used in undiagnosed acute abdominal pain, in obstruction and perforation.

Although it has been substantially proved that laparoscopic surgery is safe and efficient, having all other advantages of minimally invasive surgery, still it has some limitations. The most important one is its unavailability, this being especially true in developing countries where it also gives burden of high cost. Another technical limitation during surgery is confrontation with either too short or very broad-based Meckel's diverticulum. If its base is too short there is danger of including too much of the ileum during stapling or leaving behind its part when it is of very broad base.¹⁵

CONCLUSION

As illustrated in our case and supported by other reports, pre-operative diagnosis of patients with Meckel's diverticulum can be challenging. The diagnosis of symptomatic Meckel's diverticulum needs a high degree of suspicion as the preoperative clinical and investigational diagnosis is difficult to be made with accuracy. Symptomatic Meckel's diverticulum is rare and frequently misdiagnosed, even in developed countries. For this reason, the condition should be considered in the differential diagnosis of right lower quadrant abdominal pain and positive history of a swallowed foreign body. Appropriate knowledge of various pathophysiologies by which a Meckel's diverticulum can cause complication should be kept in mind for the better management and to prevent recurrences. If the nature of the complication is likely to require surgical management, an early laparoscopic or open exploration should be performed to prevent the morbidity and mortality associated with late complications.

List of abbreviations

MD = Meckel's diverticulum

Funding: No funding sources

Conflict of interest: None declared

Ethical approval: Not required

REFERENCES

1. Rooswick RP. Perforation of Meckel's diverticulum by foreign bodies. *Postgrad Med J.* 1965;7:105-6.
2. Mortensen NJ, Jones O. The small and large intestines. In: Russell RCG, Williams NS, Bulstrode

- CJK, eds. *Bailey & Love's Short Practice of Surgery.* 24th ed. London, UK: Hodder Arnold; 2004: 1159-1160.
3. Yahchouchy EK, Marano AF, Etienne JC, Fingerhut AL. Meckel's diverticulum. *J Am Coll Surg.* 2001;192:658-62.
4. Arnold JF, Pellicane JV. Meckel's diverticulum: a ten-year experience. *Am Surg.* 1997;63:354-5.
5. Soltero MJ, Bill AH. The natural history of Meckel's diverticulum and its relation to incidental removal. *Am J Surg.* 1976;32:168-73.
6. Cullen JJ, Kelly KA, Moir CR, Hodge DO, Zinsmeister AR, Melton LJ. Surgical management of Meckel's diverticulum. An epidemiologic, population-based study. *Ann Surg.* 1994;220:564-9.
7. Ludtke FE, Mende V, Kohler H, Lepsien G. Incidence and frequency of complications and management of Meckel's diverticulum. *Surg Gynecol Obstet.* 1989;169:537-42.
8. Evers BM. Small intestine. In: Townsend CM, eds. *Sabiston Textbook of Surgery.* 17th ed. US: Elsevier; 2004: 1366-1368.
9. Sharma RK, Jain VK. Emergency surgery for Meckel's diverticulum. *World J Emerg Surg.* 2008;3:7-27.
10. Yamaguchi M, Takeuchi S, Awazu S. Meckel's diverticulum: investigation of 600 patients in Japanese literature. *Am J Surg.* 1978;136:247-9.
11. Toshiki S, Kunihiko H, Yutakata S, Shusaku K. A case of perforation of Meckel's diverticulum by a fish bone. *J Jpn Surg Assoc.* 2004;65(9):2405-8.
12. Kazemia K, Jalaeian H, Fattahib MR, Hosseinia SV, Shafieea M, Roshana N. Ruptured Meckel's mesodiverticulum and Meckel's diverticulum following blunt abdominal trauma. *Med Princ Pract.* 2008;17:161-3.
13. Thurley PD, Halliday KE, Somers JM, Al-Daraji WI, Ilyas M, Broderick NJ. Radiological features of Meckel's diverticulum and its complications. *Clin Radiol.* 2009;64(2):109-18.
14. Elsayes KM, Menias CO, Harvin HJ, Francis IR. Imaging manifestations of Meckel's diverticulum. *AJR Am J Roentgenol.* 2007;189:81-8.
15. Ediz A, Salih P, Emre G, Feridun S. Laparoscopy-assisted resection of complicated Meckel's diverticulum in adults. *Surg Laparosc Endosc Percutan Techniq.* 2002;12(3):190-4.
16. Palanivelu C, Rangarajan M, Senthilkumar R, Madankumar MV, Kavalakat AJ. Laparoscopic management of symptomatic Meckel's diverticula: a simple tangential stapler excision. *JLS.* 2008;12(1):66-70.

Cite this article as: Rafe A, Pote MP, Takalkar UV. Perforation of Meckel's diverticulum with peritonitis: rare case report and review of literature. *Int Surg J* 2015;2:424-7.